



White Paper

TrueFidelity DL's Impact on CT Image Quality, Diagnostic Performance and Radiation Dose Optimization

The Peer-Reviewed Evidence Summary of TrueFidelity DL CT Deep Learning Image Reconstruction

Hugo Pasquier, Ph.D. and Eugene Huayang Liu, M.D.

Contents

1. Introduction	3
2. Evidence on Improving CT Image Quality	4
3. Evidence on Improving CT Diagnostic Performance	6
4. Evidence on optimizing radiation dose	8
5. Conclusion	10
6. References	10

Abstract

Since its introduction in 2018, GE HealthCare's TrueFidelity DL deep learning image reconstruction has opened a new era for CT image reconstruction.

During last four years, physics and clinical researchers worldwide have conducted multifarious studies to evaluate its impacts on CT image quality, diagnostic performance, and radiation dose optimization. The results have been published in high quality peer-reviewed articles.

The white paper is to summarize these peer- reviewed evidence and provide reference to CT researchers and clinical practitioners.



Introduction

GE HealthCare's TrueFidelity DL deep learning image reconstruction is the first US Food and Drug Administration (FDA) cleared technology to utilize a deep neural network-based reconstruction engine to generate high quality TrueFidelity DL CT images. TrueFidelity DL opens a new era for CT-image reconstruction by addressing challenges of filtered back-projection (FBP) and iterative reconstruction (IR) (Figure 1).

TrueFidelity DL features a deep neural network (DNN), which was trained with high quality FBP data sets to learn how to differentiate noise from signals, and to intelligently suppress the noise without impacting anatomical and pathological structures. The resulting TrueFidelity DL CT images, with outstanding image quality (IQ) and preferred noise texture, have the potential to improve reading confidence in a wide range of clinical applications, including imaging the head, whole body, cardiovascular, and for patients of all ages.

Since its introduction, worldwide researchers have conducted multifarious in-vitro and in-vivo studies to evaluate its impacts on CT IQ, diagnostic performance, and radiation dose optimization in various care areas. The results have been published in more than sixty peer-reviewed articles.

To provide reference to researchers and clinical practitioners who investigate conducting further studies or incorporating this technology to clinical practice, we are tasked to write up a concise white paper to summarize these peer-reviewed evidence.

This white paper will summarize the evidence of TrueFidelity DL's performance in three main sections:

1. impacts on IQ metrics (i.e. noise, spatial resolution and lesion detection);
2. impacts on diagnostic performance in neurology, pulmonary, abdominal and cardiovascular CT imaging;
3. impacts on x-ray radiation dose optimization in various clinical indications.

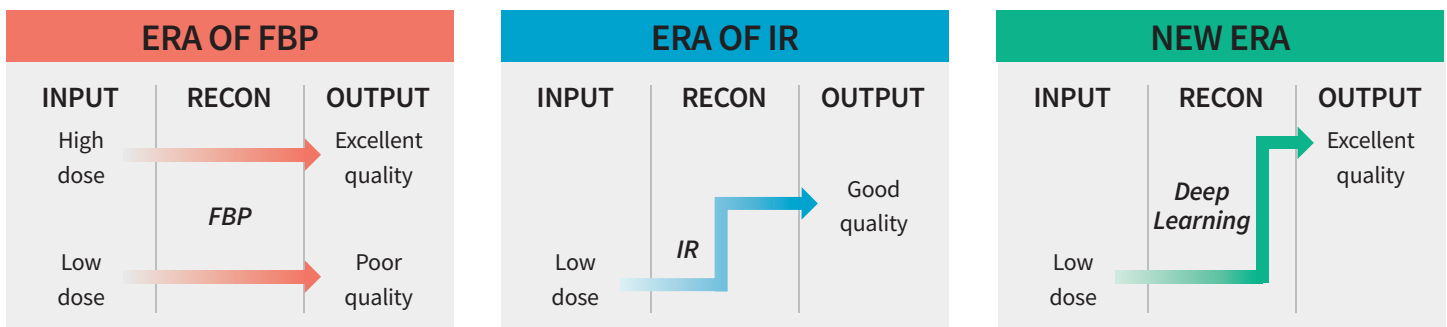


Figure 1: Generations of CT image reconstruction algorithms. The limitations of Filtered Back Projection (FBP) and Iterative Reconstruction (IR) motivated GE to explore a new era of CT deep learning image reconstruction (DLIR).

Evidence on Improving CT Image Quality

Some of the initial assessments of TrueFidelity DL IQ characteristics were conducted on phantoms.

By evaluating the noise texture through the measurement of the Noise Power Spectrum – which describes the intensity of noise as a function of spatial frequency - several studies showed that TrueFidelity DL allows reducing the image noise magnitude compared to FBP and IR while maintaining a desirable noise texture close to the one of FBP¹⁻³ (Figure 2).

Regarding spatial resolution, those studies also applied a common task-based methodology to properly measure potential dependency of dose and contrast. The results demonstrated that TrueFidelity DL improved spatial resolution compared to FBP and IR in most contrast and dose conditions assessed on an American College of Radiology (ACR) phantom and a custom quality control phantom^{1,2} (Figure 3).

The noise and spatial resolution results were further compiled in mathematical model observers computing detectability indices representative of the capability of radiologists to detect lesions of variable size and contrast. Overall, in comparison to IR, TrueFidelity DL tended to enhance the low contrast detectability of small lesions at all the dose levels tested on the ACR and the custom phantoms^{1,2} (Figure 4).

The combined benefits of noise reduction, noise texture preservation and visual spatial resolution enhancement have demonstrated to enhance the lesion detectability at various radiation dose and contrast levels tested on quality control phantoms^{1,2}.

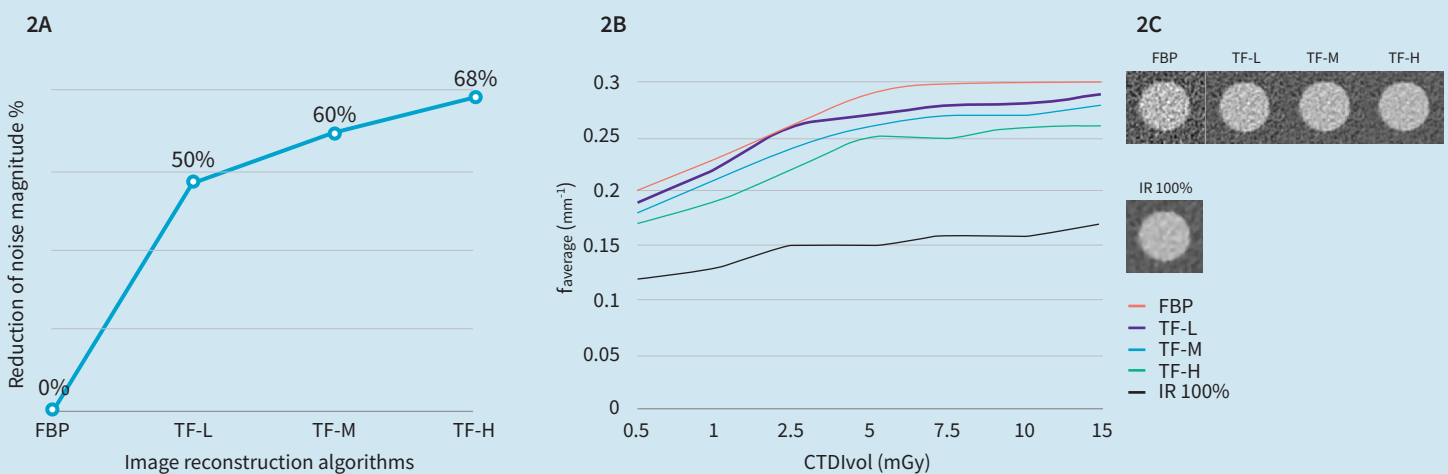


Figure 2: Impacts on image noise texture of different CT image reconstruction algorithms. Fig 2A and 2B are charts regenerated based on the phantom data published by Greffier et al.¹. Fig 2A quantifies the average image noise reduction when applying TrueFidelity at Low (TF-L), Medium (TF-M) and High (TF-H) levels respectively in comparison to FBP reconstructed images of an ACR phantom scanned at CTDIvol ranging from 0.5 to 15 mGy ; increasing the True Fidelity level from Low to High further reduces the noise magnitude in the reconstructed images. Fig 2B quantifies the noise texture of images reconstructed with FBP, IR 100%, TF-L, TF-M and TF-H by measuring the average spatial frequency of the noise power spectrum (average (mm⁻¹)) as a function of CTDIvol ; the lower the average spatial frequency, the smoother the image texture. The variation in noise magnitude and texture between reconstructions can be observed on Fig 2C: 3x3cm² regions of interest extracted from the acrylic insert of an ACR phantom scanned at a CTDIvol of 7.5mGy. While the Noise Power Spectrum tends to be shifted to lower frequencies - resulting in a smoother texture - when using high percentages of IR (i.e. IR 100%), images reconstructed with TrueFidelity, even at its higher level, have a noise power spectrum average frequency closer to the one of FBP leading to a more preferred image texture. Courtesy of Dr. Joel Greffier, CHU de Nîmes, France.

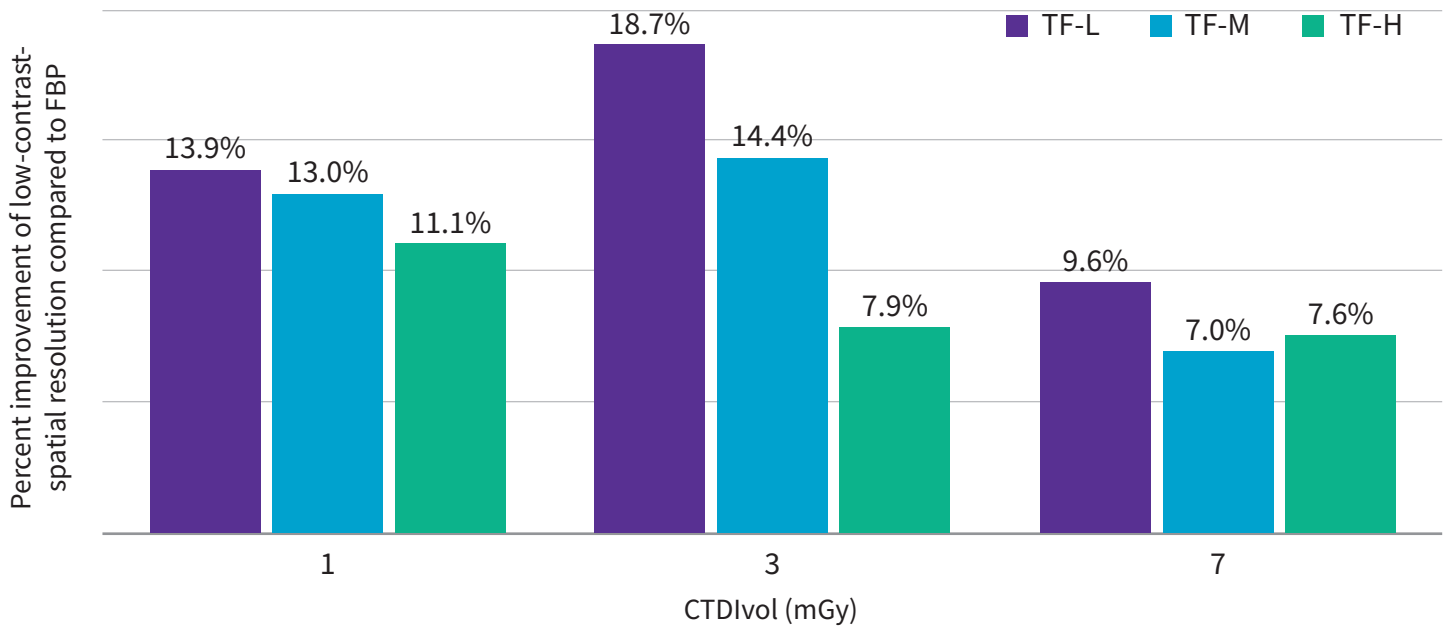


Figure 3: Impacts on low-contrast spatial resolution of different CT image reconstruction algorithms. The chart was regenerated based on the published phantom results from the paper² by Racine et al. It quantifies the low-contrast spatial resolution variability for TrueFidelity Low (TF-L), Medium (TF-M) and High (TF-H) compared to FBP by calculating the frequency at which the target transfer function reached 50% of its maximum value at three radiation dose levels. The results demonstrate that TrueFidelity may improve the visual spatial resolution in low contrast imaging task.

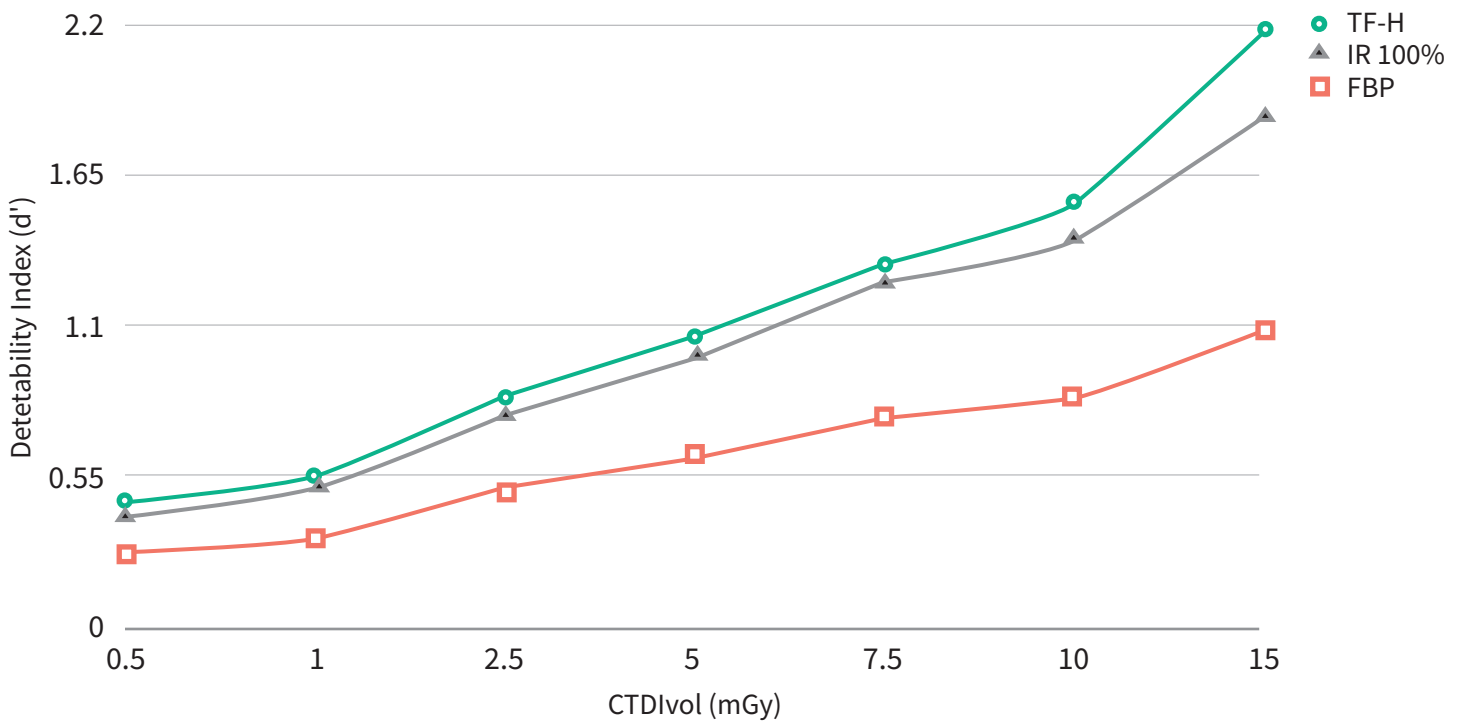


Figure 4: Impact of different CT image reconstruction algorithms on the detectability of subtle abdominal lesions. The chart was regenerated based on the phantom data published by Greffier et al.¹. It illustrates the detectability index as a function of dose for FBP, IR 100%, True Fidelity at High level (TF-H). The detectability index is a surrogate of the radiologist's capability to detect a specific lesion type; the higher the detectability index, the easier it is to detect that given lesion. Here, the detectability index was computed for a subtle 10 mm hepatic lesion with 10 HU contrast with the surrounding parenchyma¹. The results show that TrueFidelity High improves the detectability of small low contrast lesions compared to high percentage of iterative reconstruction.

Evidence on Improving CT Diagnostic Performance

Those first IQ results measured on phantoms were then observed in clinical studies.

In **abdominal imaging**, TrueFidelity DL substantially reduced noise magnitude which resulted in improved Contrast-to-Noise Ratio (CNR) and conducted radiologists to prefer the IQ and gain in diagnostic confidence, when TrueFidelity DL was applied^{4,5}. In determining the resectability of pancreatic cancer on CT, a retrospective study led by Lyu et al. involved four radiologists who reviewed 47 patients with pathologically confirmed pancreatic cancers reported that TrueFidelity DL may improve the diagnostic performance and reader confidence in the CT assignment of the local resectability of pancreatic cancer while reducing the interreader variability⁶ (Figure 5). The performance of TrueFidelity DL was also observed for renal and adrenal CT where Bie et al. showed that, among 52 patients, all exams were of diagnostic quality when reconstructed with TrueFidelity DL while almost 10% of the same exams reconstructed with IR 70% were rejected⁷.

Similar IQ improvement was observed for other clinical indications. In **chest CT**, Kim et al. demonstrated that the noise reduction provided by TrueFidelity DL resulted in superior CNR and subjective IQ, allowing to ease the identification of the pulmonary vessels, trachea, bronchi, lymph nodes, pleura and pericardium⁸. Jiang et al. also demonstrated a noise reduction and an improvement of subjective IQ using TrueFidelity DL compared to IR 80% in ultra-low dose conditions. This improvement was associated with an increased lung nodule detection rate, more accurate nodule measurements and a better visibility of malignancy related imaging features at 0.14 mSv⁹ (Figure 6).

In **coronary computed tomography angiography (CCTA)**, a retrospective study including 43 patients, with suspected or known coronary artery disease and who underwent invasive coronary angiography, showed that TrueFidelity DL significantly reduced noise compared to IR, while yielding superior IQ at equal diagnostic accuracy¹⁰. Comparable results were observed in 80 patients scanned at low-tube-voltage conditions¹¹ and in 60 obese patients without increasing in the radiation dose¹² (Figure 7).

When using TrueFidelity DL for **CT angiography of the aorta**, compared to state-of-the-art IR algorithm, Heinrich et al. observed a reduction in image noise, an increase of Signal-to-Noise Ratio and CNR and an improvement of subjective IQ that could lead to an optimization of radiation and contrast agent doses, in 51 consecutive adult patients¹³.

Finally, TrueFidelity DL reduced noise, improved the IQ while reducing streak artifact in routine **brain CT** in 62 patients with CT findings such as mildly enlarged ventricles and widened cortical sulci, physiologic calcifications in the medial basal ganglia, and a few scattered patchy white matter hypodensities which can be seen in normal aging brains¹⁴. TrueFidelity DL also reduced the number of non-diagnostic exams among 94 patients who underwent non-contrast head scans as part of their trauma protocols¹⁵.

Improved diagnostic performance was reported in various clinical indications ranging from trauma head scans, ultra-low-dose chest CT, low kV CCTA, to abdominal exams such as pancreatic cancer evaluation, renal and adrenal exams⁴⁻¹⁵.

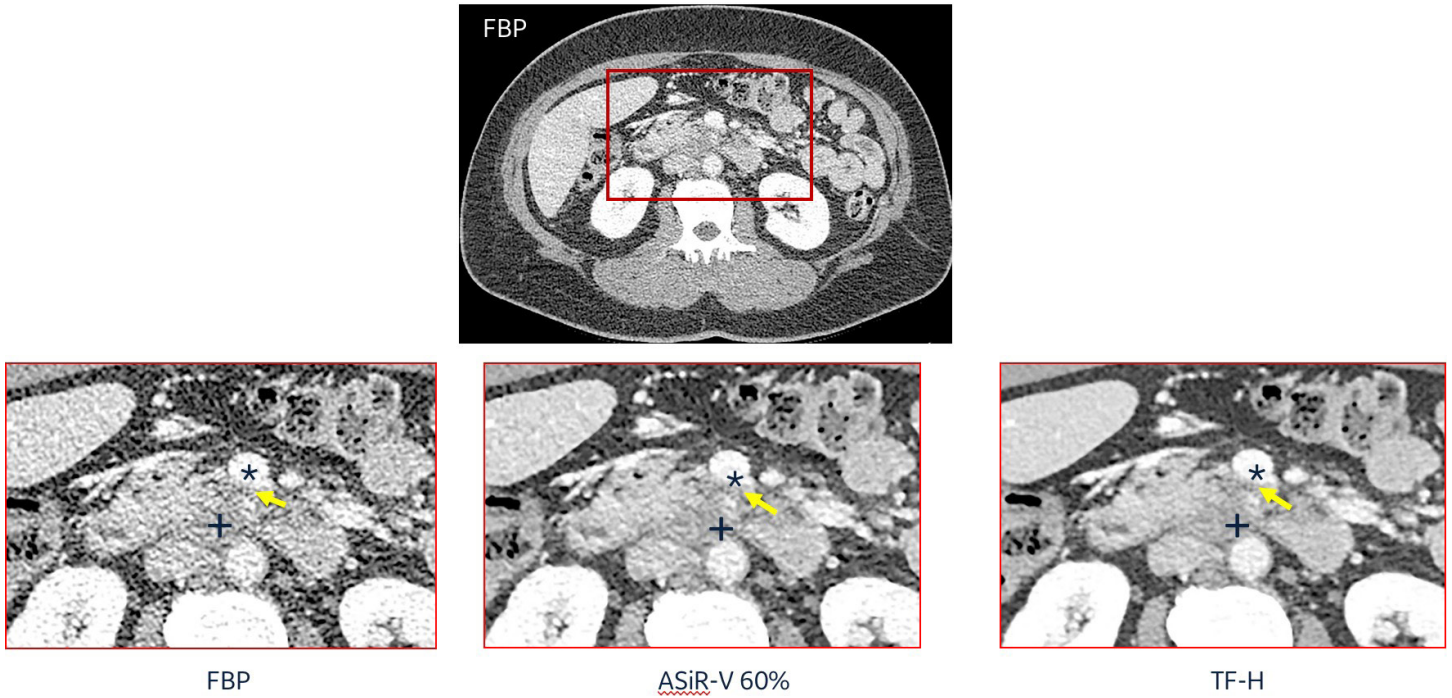


Figure 5: Comparison of CT image reconstruction algorithms in abdominal CT imaging for pancreatic cancer resectability evaluation. A 52-year-old female patient with pancreatic ductal adenocarcinoma in the pancreatic head (+) received three phases abdominal CT exam: non-contrast phase, pancreatic parenchymal phase and hepatic portal venous phase. The images in hepatic portal venous phases were reconstructed with FBP, ASiR-V 60% and TF-H. Readers marked the highest confidence in TF-H image in determining the short sentimental contact between peripancreatic infiltration (yellow arrows) and superior mesenteric vein (*). Courtesy of Dr. Peijie Lyu.

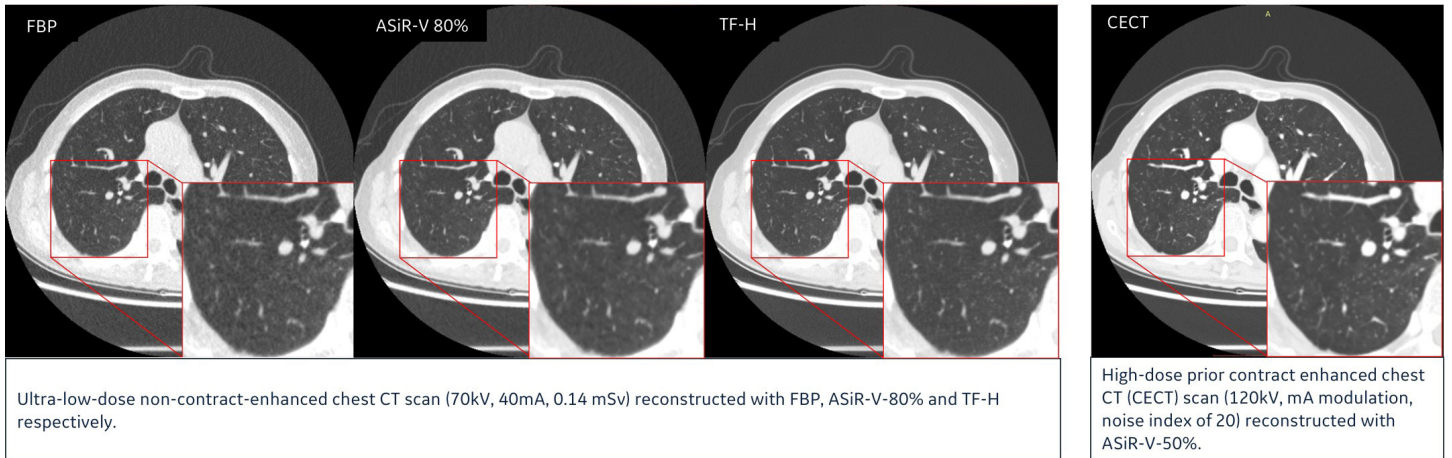


Figure 6: Comparison of CT image reconstruction algorithms in ultra-low-dose (0.14 mSv) chest CT. A 72-year-old male patient with BMI 19 kg/m² and a clinical history of lung cancer surgery in the right middle lobe, received prior high dose CECT (reconstructed with ASiR-V-50%) and ultra-low dose (0.14 mSv) non-contrast chest CT (reconstructed with FBP, ASiR-V-80%, TF-H). The red outlined area shows the details of the magnified images of lung parenchyma. The ultra-low dose TF-H image shows clearer lung parenchyma and details, comparable to the high dose CECT image. Courtesy of Dr. Xueqian Xie, the Department of Radiology, Shanghai General Hospital, Shanghai, China.

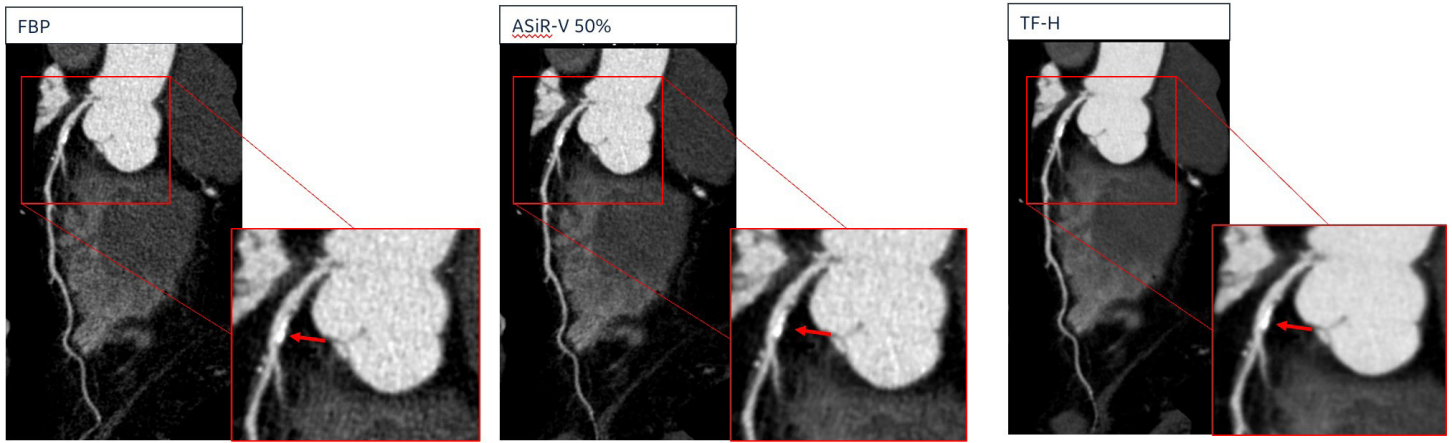


Figure 7: Comparison of CT image reconstruction algorithms in 80kVp CCTA. A 59-year-old male patient (BMI 26.9 kg/m², HR: 69 bpm) received a CCTA exam (80kV, 240-305 auto mA, 14cm detector coverage, 0.28s/rot, 75%-80% exposure window), and images were reconstructed with FBP, ASiR-V 50% and TF-H. LAD image shows the calcified plaque (red arrow). Compared to FBP and ASiR-V, TF-H demonstrates the clearer boundary distinction between the vessel and calcified plaque with less beam hardening artifacts. Courtesy of Dr. Wenjie Yang, the Department of Radiology, Ruijin Hospital, Shanghai, China.

Evidence on Optimizing Radiation Dose

Initial evaluations of TrueFidelity DL's impacts on x-ray radiation dose reduction opportunities were led on phantoms.

Using a clinical task-based methodology applied on an ACR phantom placed inside a body ring and scanned at CTDIvol ranging from 0.5 to 15 mGy, Greffier et al. reported dose reduction potentials of 46% to 56% for the detection of different lesion types (circular lesions of 500 HU – 1.5 mm ; 120 HU – 25 mm and 10 HU-10 mm) with the High level of TrueFidelity DL compared to IR 50% at a baseline CTDIvol of 10 mGy¹.

Applying a similar methodology on a custom 25-cm- diameter cylindrical phantom, Racine et al. demonstrated that TrueFidelity at Medium and High levels would ensure a 100% detection rate of small lesions (50 HU – 5mm) at ultra-low dose (CTDIvol = 1mGy). Compared to IR 50%, the High level of TrueFidelity DL would allow to reduce radiation dose by up to 61%².

Following initial phantom studies, comprehensive clinical studies covering a wide range of clinical indications have been conducted to explore TrueFidelity DL's impacts on radiation dose optimization.

Table 1 summarizes the methodologies and key findings of nine clinical studies.

In **cardiac CT**, Benz et al. demonstrated that the High level of TrueFidelity DL could enable radiation dose reduction in CCTA by 43% without significant impact on image noise, stenosis evaluation, plaque composition, and quantitative plaque volume¹⁶. The work led by Li et al. reported that the use of 70-kVp tube voltage combined with the High level of TrueFidelity DL for CCTA in normal-sized patients could reduce radiation dose by 54.5% and iodine contrast medium usage by 50.6% while further improving IQ compared with the conventional 120-kVp tube voltage with IR 60%¹⁷. Comparably, Sun et al. demonstrated that a significant reduction in iodine contrast medium usage of 53% and radiation dose of 36% could be achieved while maintaining similar IQ and diagnostic confidence in pediatric exams by using the High level of TrueFidelity DL, compared with the conventional CCTA protocol using IR 50%¹⁸.

In **abdominal imaging**, Nam et al. showed that, with less than 50% of the radiation dose, the High level of TrueFidelity DL showed comparable IQ in the upper abdomen to that of dedicated abdominal CT reconstructed with IR 40% and was preferred by most readers¹⁹. Similarly, Cao et al. demonstrated that the High level of TrueFidelity DL could significantly reduce image noise and generate images with clinically acceptable IQ and diagnostic confidence with 76% dose reduction compared to IR 50% in contrast-enhanced abdominal CT for patients with hepatic lesions²⁰. Additionally, the Medium level of TrueFidelity DL improved IQ at 65% reduced radiation dose while preserving detection of liver lesions larger than 0.5 cm in a study led by Jensen et al.²¹. For the evaluation of urinary tract lithiasis, tumor or hematuria, Cheng et al. analyzed the excretory phase images of 52 CT urography exams where half of the patients were scanned using a routine protocol and the other half had a low dose exam. The results reported the feasibility to reduce 71% radiation dose while maintaining the same IQ in low-dose exams with the High level of TrueFidelity DL in comparison with conventional protocols with IR 50%²².

In **chest CT scan**, Wang et al. showed that images acquired at 0.54 mGy and reconstructed with the High level of TrueFidelity DL provided similar IQ than images acquired at 12.46 mGy and reconstructed with IR 40%²³. Yeom et al. demonstrated that ultra-low dose levels can be achieved to assess morphological changes of the parenchyma when using TrueFidelity DL as it ensured relevant measurements of lung volumes, attenuation and emphysema indices²⁴. Finally, the study conducted by Tschauner et al. showed that effective radiation dose could approach 0.1-0.3 mSv without compromising IQ in pediatric chest CT exams²⁵.

TrueFidelity DL was reported to achieve radiation dose reduction ranging from 38% to 96%¹⁶⁻²⁴.*

*The dose reduction evidence represents the findings of the reported single center studies and is varied by clinical indications, study protocols and comparison methods. The results obtained in these studies are not generalizable and may not be reproducible.

Table 1: Summary of clinical studies that evaluated TrueFidelity's performance in optimizing CT radiation dose

Clinical indications	Population	Cohort size	Radiation dose used in normal dose protocol	IR strength (%) used in normal dose protocol	Radiation dose used in low dose protocol	TrueFidelity level used in low dose protocol	Radiation dose reduction (%) by comparing low dose against normal dose	Ref.
CCTA	Adult	50	1.4 mSv	ASIR-V 100%	0.8 mSv	TrueFidelity - High	43%	16
CCTA	Adult	100	7.62 mGy	ASIR-V 60%	3.68 mGy	TrueFidelity - High	55%	17
CCTA	Pediatric	27	2.24 mGy	ASIR-V 50%	1.40 mGy	TrueFidelity - High	38%	18
General abdomen	Adult	2 groups of 50	7.10 mGy	ASIR-V 40%	3.19 mGy	TrueFidelity - High	50%	19
Detection of small hepatic cysts	Adult	40	3.18 mSv	ASIR-V 50%	0.76 mSv	TrueFidelity - High	76%	20
Detection of liver metastases (>0.5mm)	Adult	51	34.9 mGy	ASIR-V 60%	12.2mGy	TrueFidelity - Medium	65%	21
Urography	Adult	2 groups of 26	9.6 mGy	ASIR-V 50%	2.95 mGy	TrueFidelity - High	71%	22
General chest	Adult	48	12.46 mGy	ASIR-V 40%	0.54 mGy	TrueFidelity - High	96%	23
Emphysema quantification	Adult	32	3.43 mSv	ASIR-V 50%	0.39 mSv	TrueFidelity - Low	89%	24

Conclusion

The era of deep learning-based CT image reconstruction has arrived in clinical practice. TrueFidelity DL has pioneered this domain to demonstrate the proven benefits. The initial peer-reviewed evidence from physics and clinical studies have provided promising insights of how TrueFidelity DL may improve CT IQ and help radiologists to enhance diagnostic confidence and performance in challenging imaging tasks. The radiation dose reduction capability may give CT users a new powerful tool to optimize the CT protocols and minimize the radiation dose without compromising the IQ and diagnostic performance.

References

1. Greffier, J. et al. Image quality and dose reduction opportunity of deep learning image reconstruction algorithm for CT: a phantom study. *Eur. Radiol.* 30, 3951–3959 (2020).
2. Racine, D. et al. Task-based characterization of a deep learning image reconstruction and comparison with filtered back-projection and a partial model-based iterative reconstruction in abdominal CT: A phantom study. *Phys. Med.* 76, 28–37 (2020).
3. Solomon, J., Lyu, P., Marin, D. & Samei, E. Noise and spatial resolution properties of a commercially available deep learning-based CT reconstruction algorithm. *Med. Phys.* 47, 3961–3971 (2020).
4. Jensen, C. T. et al. Image Quality Assessment of Abdominal CT by Use of New Deep Learning Image Reconstruction: Initial Experience. *Am. J. Roentgenol.* 215, 50–57 (2020).
5. Parakh, A. et al. Sinogram-based deep learning image reconstruction technique in abdominal CT: image quality considerations. *Eur. Radiol.* 31, 8342–8353 (2021).
6. Lyu, P. et al. Effect of deep learning image reconstruction in the prediction of resectability of pancreatic cancer: Diagnostic performance and reader confidence. *Eur. J. Radiol.* 141, 109825 (2021).
7. Bie, Y. et al. Impact of deep learning-based image reconstruction on image quality compared with adaptive statistical iterative reconstruction-Veo in renal and adrenal computed tomography. *J. X-Ray Sci. Technol.* 30, 409–418 (2022).
8. Kim, J. H. et al. Validation of Deep-Learning Image Reconstruction for Low-Dose Chest Computed Tomography Scan: Emphasis on Image Quality and Noise. *Korean J. Radiol.* 22, 131–138 (2021).
9. Jiang, B. et al. Deep Learning Reconstruction Shows Better Lung Nodule Detection for Ultra-Low-Dose Chest CT. *Radiology* 303, 202–212 (2022).
10. Benz, D. C. et al. Validation of deep-learning image reconstruction for coronary computed tomography angiography: Impact on noise, image quality and diagnostic accuracy. *J. Cardiovasc. Comput. Tomogr.* 14, 444–451 (2020).
11. Wang, M. et al. A deep-learning reconstruction algorithm that improves the image quality of low-tube-voltage coronary CT angiography. *Eur. J. Radiol.* 146, 110070 (2022).
12. Wang, H. et al. Assessment of Image Quality of Coronary Computed Tomography Angiography in Obese Patients by Comparing Deep Learning Image Reconstruction With Adaptive Statistical Iterative Reconstruction Veo. *J. Comput. Assist. Tomogr.* 46, 34–40 (2022).
13. Heinrich, A. et al. Deep Learning-Based Image Reconstruction for CT Angiography of the Aorta. *Diagn. Basel Switz.* 11, 2037 (2021).
14. Kim, I., Kang, H., Yoon, H. J., Chung, B. M. & Shin, N.-Y. Deep learning-based image reconstruction for brain CT: improved image quality compared with adaptive statistical iterative reconstruction-Veo (ASIR-V). *Neuroradiology* 63, 905–912 (2021).
15. Alagic, Z. et al. Deep learning versus iterative image reconstruction algorithm for head CT in trauma. *Emerg. Radiol.* 29, 339–352 (2022).
16. Benz, D. C. et al. Radiation dose reduction with deep-learning image reconstruction for coronary computed tomography angiography. *Eur. Radiol.* 32, 2620–2628 (2022).
17. Li, W. et al. High-strength deep learning image reconstruction in coronary CT angiography at 70-kVp tube voltage significantly improves image quality and reduces both radiation and contrast doses. *Eur. Radiol.* 32, 2912–2920 (2022).
18. Sun, J. et al. Performance evaluation of using shorter contrast injection and 70 kVp with deep learning image reconstruction for reduced contrast medium dose and radiation dose in coronary CT angiography for children: a pilot study. *Quant. Imaging Med. Surg.* 11, 4162171–4164171 (2021).
19. Nam, J. G., Hong, J. H., Kim, D. S., Oh, J. & Goo, J. M. Deep learning reconstruction for contrast-enhanced CT of the upper abdomen: similar image quality with lower radiation dose in direct comparison with iterative reconstruction. *Eur. Radiol.* 31, 5533–5543 (2021).
20. Cao, L. et al. A study of using a deep learning image reconstruction to improve the image quality of extremely low-dose contrast-enhanced abdominal CT for patients with hepatic lesions. *Br. J. Radiol.* 94, 20201086 (2021).
21. Jensen, C. T. et al. Reduced-Dose Deep Learning Reconstruction for Abdominal CT of Liver Metastases. *Radiology* 303, 90–98 (2022).
22. Cheng, Y. et al. Low-dose CT urography using deep learning image reconstruction: a prospective study for comparison with conventional CT urography. *Br. J. Radiol.* 94, 20201291 (2021).
23. Wang, H., Li, L.-L., Shang, J., Song, J. & Liu, B. Application of deep learning image reconstruction in low-dose chest CT scan. *Br. J. Radiol.* 95, 20210380 (2022).
24. Yeom, J.-A. et al. Emphysema Quantification Using Ultra-Low-Dose Chest CT: Efficacy of Deep Learning-Based Image Reconstruction. *Medicina (Mex.)* 58, 939 (2022).
25. Tschauer, S. et al. Ultra-low-dose lung multidetector computed tomography in children - Approaching 0.2 millisievert. *Eur. J. Radiol.* 139, 109699 (2021).

